

Mercury Inhalation Poisoning and Acute Lung Injury in a Child*

Use of High-Frequency Oscillatory Ventilation

David Y. Moromisato, M.D.; Nick G. Anas, M.D.; and Gary Goodman, M.D.

Acute mercury inhalation poisoning is a rare cause of acute lung injury. It is commonly fatal in the young child because of progressive pulmonary failure. We describe a 3-month-old infant who survived this insult with the use of high-frequency oscillatory ventilation. This form of support may be an option in the patient with severe adult respiratory distress syndrome (ARDS) or air leak syndromes. (*Chest* 1994; 105: 613-15)

ECMO = extracorporeal membrane oxygenation; HFOV = high-frequency oscillatory ventilation; P_{aw} = mean airway pressure; SaO_2 = arterial oxygen saturation

The toxic effects of acute mercury vapor inhalation have been described.¹⁻⁶ Although unusual in adults, mercury inhalation injury in young children is commonly fatal. The majority of deaths are due to severe and progressive acute lung injury. We report the findings in a 3-month-old infant with severe mercury inhalation injury who survived with the support of high-frequency oscillatory ventilation (HFOV).

CASE REPORT

A 3-month-old infant was seen in the emergency room of a community hospital with the acute onset of tachypnea and irritability 4 h after the grandfather had been extracting gold from ore by heating mercury in the kitchen. The infant was admitted to the hospital for acute mercury vapor inhalation poisoning and was then transferred to the Children's Hospital of Orange County for tertiary care. Upon admission to the pediatric intensive care unit of that hospital, the infant was irritable, with a grunting respiratory effort and intercostal retractions. The respiratory rate was 76/min. Initial arterial blood gas tensions while breathing oxygen via a mask (8 L/min) were as follows: pH 7.33; $PaCO_2$, 33 mm Hg; and PaO_2 , 367 mm Hg. A chest roentgenogram (CXR) revealed a left lower lobe infiltrate with diffusely increased central lung markings (Fig 1). The patient was changed to oxygen via nasal cannula at 1 L/min, and the flow was adjusted to maintain the arterial oxygen saturation (SaO_2) greater than 90 percent.

Approximately 24 h after admission, the infant's respiratory rate had increased to 100/min, and his work of breathing by physical examination was excessive. A CXR showed a left-sided pneumothorax with diffuse granular opacification and bilateral air bronchograms. A thoracostomy tube was inserted, the patient's trachea was intubated, and pharmacologic paralysis was employed to optimize mechanical ventilation and to minimize the patient's work of breathing.

Over the next 2 days, the infant developed bilateral pneumothoraces with extensive pneumomediastinum and a continuous air leak on the left. His CXR showed diffuse opacification of the lung fields with enlarging bilateral cyst formations in the lung bases (Fig 2). Settings on the ventilator (VIP Bird Infant/Pediatric Ventilator) were a fractional concentration of oxygen in the inspired gas (FI_{O_2}) of 0.84, mandatory

*From the Pediatric Intensive Care Unit, Children's Hospital of Orange County, Torrance, Calif.
Reprint Requests: Dr. Moromisato, Harbor-UCLA Medical Center N4, Box 491, 1124 West Carson, Torrance, CA 90502

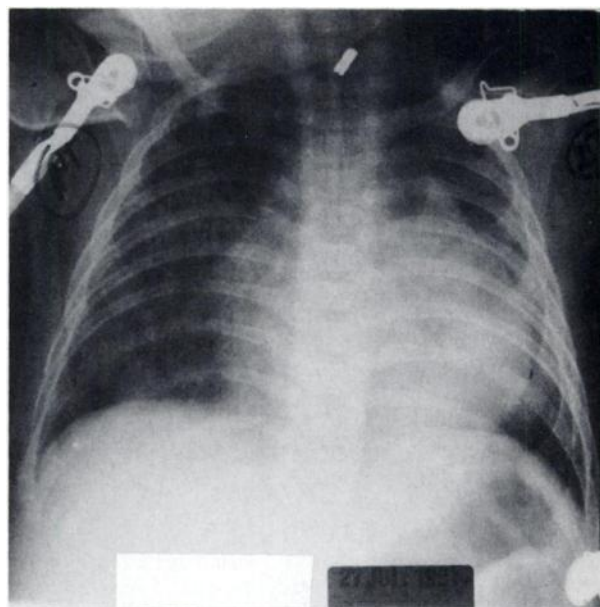


FIGURE 1. Anteroposterior portable CXR on admission.

rate of 40/min, inspiratory:expiratory ratio of 1:2, positive end-expiratory pressure (PEEP) of 10 cm H_2O , peak inspiratory pressure of 42 cm H_2O , and a tidal volume of 10 ml/kg of body weight. Arterial blood gas analysis showed a pH of 7.39, $PaCO_2$ of 47 mm Hg, and PaO_2 of 73 mm Hg.

Because of life-threatening air leaks, the requirement for high inspiratory and expiratory pressure settings, and the need for supplemental oxygen at nearly 100 percent for greater than 48 h, the patient was placed on HFOV (SensorMedics 3100A Oscillatory Ventilator), with immediate improvement in SaO_2 (Fig 3). The settings on the ventilator were 5 Hz (300 oscillations per minute), mean airway pressure (P_{aw}) of 25 cm H_2O , pressure amplitude of 102 cm H_2O , and FI_{O_2} of 0.84.

Over the next 24 h on HFOV, the patient's ventilatory support was decreased to a P_{aw} of 25 cm H_2O , pressure amplitude of 50 cm H_2O , and FI_{O_2} of 0.31. Arterial blood gas analysis on these settings revealed

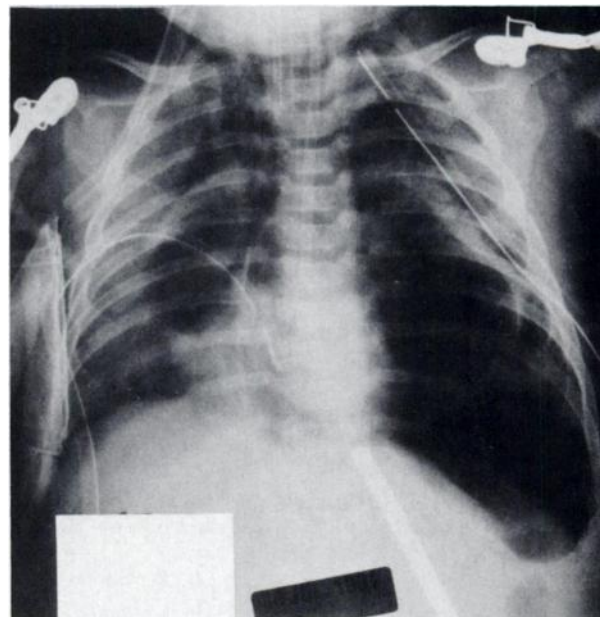


FIGURE 2. Chest x-ray film obtained shortly after initiating HFOV support.

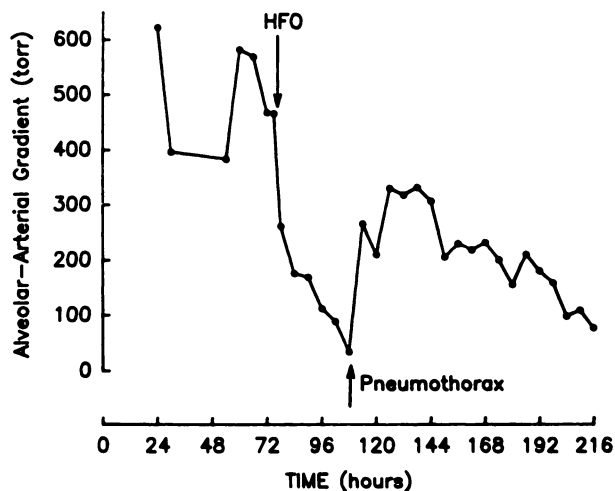


FIGURE 3. Patient was intubated 24 h into hospitalization. High-frequency oscillatory ventilation (HFOV) was initiated at 72 h. Alveolar-arterial oxygen pressure gradient had decreased to 35 mm Hg prior to pneumothorax, which occurred 30 h after starting HFOV.

a pH of 7.43, PaCO₂ of 42 mm Hg, and PaO₂ of 80 mm Hg. Despite clinical improvement, the CXR showed continued enlargement of the subpulmonic cyst formations, and later in the day, the patient developed a left tension pneumothorax requiring an additional chest tube; however, the P_{aw} and F_{IO₂} were reduced as tolerated, and the air leaks resolved over the following 6 days. After a total of 12 days of HFOV and resolution of the pulmonary interstitial emphysema and tension cysts, the patient was placed on conventional ventilatory support and was extubated 6 days later without problems. He was discharged home on the 29th day of hospitalization, with a normal CXR and normal findings on physical examination.

DISCUSSION

Many household acute mercury vapor inhalation poisonings result from attempts to separate gold from gold ore by heating mercury and forming a gold-mercury amalgam; the toxic effects of mercury inhalation have been described.^{3,6-8} Unlike adults, the mortality in young children exposed to excessive mercury vapor is high.^{4,5} The cause of death in all lethal cases is progressive pulmonary failure, and the pathologic findings in the lungs at autopsy reveal various stages of acute lung injury, similar to those found in the adult respiratory distress syndrome (ARDS).⁶

Our patient had clinical evidence of both ARDS and extrapulmonary air. Because of the patient's worsening pneumothoraces, increasing oxygen requirements (alveolar-arterial oxygen pressure gradient [$P(A-a)O_2$] > 500 mm Hg), and the previous experience documented in the literature suggesting a poor outcome, an unconventional mode for ventilation was chosen. We were impressed with this infant's rapid response to HFOV. Within hours, gas exchange had markedly improved, resulting in reduced oxygen requirement and barotrauma. The use of HFOV to support patients with acute mercury inhalation injury has not been reported; however, HFOV has been used to manage infant respiratory distress syndrome and air leak syndromes.⁹⁻¹³

There are several rationales for the use of HFOV. First, it enables the physician to use high P_{aw} to attain adequate oxygenation while using lower peak inspiratory pressures to minimize barotrauma. Secondly, smaller tidal volumes reduce the

pressure gradient across the injury site, and as shown by Dreyfuss *et al.*,¹⁴ tidal volume independent of inspiratory pressure contributes to further lung injury. Finally, HFOV reduces the time that the airway pressure remains above the air leak "threshold." Attaining maximal gas exchange and minimizing barotrauma with the use of HFOV are achieved by a variety of strategies, and detailed descriptions on the use of high-frequency oscillation have been published.⁹

A number of therapies are now available to provide respiratory support in patients with severe pulmonary injury.¹⁵ Extracorporeal membrane oxygenation (ECMO) has been used as an option to manage severe ARDS and life-threatening hypoxemia.^{13,16} Extracorporeal membrane oxygenation has also been used in treating specific neonatal diseases which have a high mortality but are reversible (*eg*, persistent pulmonary hypertension of the newborn).¹⁷ Because older infants and children have more varied disease processes, the prediction of morbidity, mortality, and reversibility of lung injury is difficult. The reversal of pulmonary disease in ARDS is a process which may take weeks, thereby making ECMO a less desirable choice for the support of patients with ARDS. The possibility of morbidity or mortality resulting from infection, hemorrhage, or myocardial failure increases when ECMO is employed for prolonged periods.¹⁸ Furthermore, clinical trials using ECMO in severe ARDS in adult patients failed to show any advantage over conventional therapy.¹⁹ Finally, recent trials with extracorporeal CO₂ removal also found it to be no more beneficial than a computerized protocol for mechanical ventilatory management.²⁰ Therefore, the benefit of extracorporeal circuits to manage severe, acute lung injury in children is unknown, pending prospective randomized trials.

In summary, we report this case of acute mercury inhalation injury to highlight the potential value of HFOV in acute lung syndromes in the pediatric patient unresponsive to conventional therapies. As in the adult population, children with ARDS characterized by severe hypoxemia have a high mortality, despite improvements in intensive care and conventional mechanical ventilation. Alternative therapies such as HFOV, or perhaps ECMO may allow for lung healing to occur by minimizing barotrauma and the adverse effects of supplemental oxygen.

REFERENCES

- 1 Campbell JS. Acute mercurial poisoning by inhalation of metallic vapor in an infant. *Can Med Assoc J* 1948; 58:72-5
- 2 Matther FT, Kirscher R, Yow MD, Brennan JC. Acute poisoning associated with inhalation of mercury vapor: report of 4 cases. *Pediatrics* 1958; 22:675-88
- 3 Moutinho ME, Tompkins AL, Roivland TW, Bansom BB, Jackson HA. Acute mercury vapor poisoning: fatality in an infant. *Am J Dis Child* 1981; 135:42-4
- 4 Jung RC, Aaronson J. Death following inhalation of mercury vapor at home. *West J Med* 1980; 132:539-43
- 5 Rowens B, Guerraro-Betancourt D, Gottlieb CA, Boyes RJ, Eichenhorn MS. Respiratory failure and death following acute inhalation of mercury vapor. *Chest* 1991; 99:185-90
- 6 Kanluen S, Gottlieb CA. A clinical pathologic study of four adult cases of acute mercury inhalation toxicity. *Arch Pathol Lab Med* 1991; 115:56-60
- 7 Jaffe KM, Shurtleff DB, Robertson WO. Survival after acute mercury vapor poisoning. *Am J Dis Child* 1983; 137:749-51
- 8 Lien DC, Todoruk DN, Rajani HR, Cook DA, Herbert HA.

- Accidental inhalation of mercury vapor: respiratory and toxicologic consequences. *Can Med Assoc J* 1983; 129:591-95
- 9 Gerstmann DR, deLemos RA, Clark RH. High-frequency ventilation: issues of strategy. *Clin Perinatol* 1991; 18:563-80
 - 10 Mayes TC, Jefferson LS. Management of malignant air leak in a child with neonatal high frequency oscillatory ventilator. *Chest* 1991; 100:263-64
 - 11 Clark RH, Gerstmann DR, Null DM, Yoder BA, Cornish JD. Pulmonary interstitial emphysema treated with high frequency oscillatory ventilation. *Crit Care Med* 1986; 14:926-30
 - 12 Clark RH, Gerstmann DR, Null DM, deLemos RA. Prospective randomized comparison of high-frequency oscillatory and conventional ventilation in respiratory distress syndrome. *Pediatrics* 1992; 89:5-12
 - 13 HIFI Study Group. High-frequency oscillatory ventilation compared with conventional mechanical ventilation in the management of respiratory failure in preterm infants. *N Engl J Med* 1989; 320:88-93
 - 14 Dreyfuss D, Soler P, Basset G, Saumon G. High inflation pressure pulmonary edema: respective effects of high airway pressure, tidal volume, and positive end-expiratory pressure. *Am Rev Respir Dis* 1988; 137:1159-64
 - 15 Marini JJ, Kelson SG. Re-targeting ventilatory objectives in adult respiratory distress syndrome: new treatment prospects—persistent questions. *Am Rev Respir Dis* 1992; 146:2-3
 - 16 Steinhorn RH, Green TP. Use of extracorporeal membrane oxygenation in the treatment of respiratory syncytial virus bronchiolitis: the national experience, 1983 to 1988. *J Pediatr* 1990; 116:338-42
 - 17 O'Rourke PP, Crone RK, Vacanti JP, Ware JH, Lillehei CW, Parad RB, et al. Extracorporeal membrane oxygenation and conventional medical therapy in neonates with persistent pulmonary hypertension of the newborn: a prospective randomized study. *Pediatrics* 1989; 84:957-63
 - 18 Donn SM. ECMO indications and complications. *Hosp Pract* 1990; 25:143-57
 - 19 Zapol WM, Snider MT, Hill JD. ECMO in severe acute respiratory failure. *JAMA* 1979; 242:2193-96
 - 20 Morris AH, Wallace CH, Clemmer TP. Final report: computerized protocol controlled clinical trial of new therapy which includes ECCO₂R for ARDS [abstract]. *Am Rev Respir Dis* 1992; 145:A184

Staphylococcus aureus* Pericarditis in HIV-infected Patients

Catherine F. Decker, M.D.; and Carmelita U. Tuazon, M.D.

Serious infections caused by *Staphylococcus aureus* in HIV-infected patients have been reported. Contributing factors in the development of invasive *S aureus* infections include a high rate of skin and nasal colonization, frequent dermatologic disease, and the use of intravenous catheters. The authors report three cases of *S aureus* pericarditis in HIV-infected patients. While cases of viral, mycobacterial, and malignant pericardial effusions in HIV-infected patients have been reported, a review of the literature disclosed only three cases of bacterial pericarditis. Despite appropriate antibiotic therapy and drainage, a patient's condition may abruptly

deteriorate and progress to tamponade. Early recognition of bacteremia and pericarditis and monitoring for cardiac tamponade, along with aggressive treatment, can result in a favorable outcome, but mortality remains high, particularly when *S aureus* is the causative agent. (*Chest* 1994; 105: 615-16)

Serious infections, such as bacteremias and soft-tissue infections, caused by *Staphylococcus aureus* in HIV-infected patients have been reported recently.^{1,2} Risk factors include a high rate of skin and nasal colonization,^{3,4} frequent dermatologic disease,⁵ and the use of intravenous catheters.¹

While cases of viral, mycobacterial, and malignant pericardial effusions in HIV-infected patients have been reported, bacterial pericarditis is rare.^{6,7} Three cases of *S aureus* pericarditis in HIV-infected patients and a review of the literature are presented.

CASE REPORTS

CASE 1

A 35-year-old HIV-seropositive black man, an intravenous heroin and cocaine user, was admitted for dyspnea, malaise, and chest pain of 3 weeks' duration. There was no history of opportunistic infection, except for oral candidiasis. Significant findings included oral candidiasis, pustular lesions on the extremities, and a pericardial friction rub. The chest radiograph revealed an enlarged cardiac silhouette, a small pleural effusion, and a retrocardiac alveolar infiltrate. The Po₂ was 70 mm Hg on room air. The ECG showed sinus tachycardia with global 1- to 2-mm ST-segment elevation. A two-dimensional echocardiogram revealed moderate pericardial effusion without hemodynamic compromise.

Intravenous trimethoprim-sulfamethoxazole was begun for presumptive *Pneumocystis carinii* pneumonia. Multiple sets of blood, urine, and sputum cultures were positive for *S aureus*. Trimethoprim-sulfamethoxazole was discontinued, and intravenous vancomycin was instituted. Pericardiocentesis yielded 350 ml of clear yellow exudative fluid, which grew *S aureus*. When the antibiotic susceptibility results were obtained, vancomycin was replaced by nafcillin. A pericardial window was performed when a repeat echocardiogram revealed a reaccumulation of pericardial fluid. Repeat blood and pericardial fluid cultures were sterile. The patient did well and was discharged in good condition.

CASE 2

A 39-year-old black man with AIDS and cutaneous Kaposi's sarcoma was admitted because of dyspnea, fever, and cough. Significant findings were fever of 39.4°C, pulsus paradoxus, diffuse rhonchi, and an S3-S4 gallop with pericardial rub. A chest radiograph revealed an enlarged cardiac silhouette and bilateral lower lobe and lingular infiltrates. An ECG showed sinus tachycardia, diffuse ST-segment elevation, and diffuse PR depression.

An echocardiogram revealed a large pericardial effusion. Emergent pericardiocentesis yielded 300 ml of serosanguineous fluid with marked relief of respiratory symptoms. Sputum and pericardial fluid cultures grew *S aureus*, and intravenous nafcillin was administered. Nafcillin was replaced with vancomycin after the patient developed a diffuse rash.

The patient's clinical course deteriorated and was complicated by development of *Candida albicans* empyema. An open-lung biopsy also showed cytomegalovirus pneumonitis. Intravenous ganciclovir therapy was begun. His respiratory status continued to decline, and he died 7 weeks after admission.

CASE 3

A 35-year-old HIV-positive female drug abuser presented with fever, headache, and cough. She had a history of *S aureus* endocarditis.

* From the Division of Infectious Diseases, National Naval Medical Center, Bethesda, Md, and George Washington University Medical Center, Washington, DC.

Reprint requests: Dr. Tuazon, 2150 Pennsylvania Avenue, NW, Washington, DC 20037